

Gaspar Ibarluzea, MD.

Barcelona

25th Anniversary EAU Congress

16-20 April 2010

25th Anniversary EAU Congress

EAU

European
Association
of Urology

©

PCNL

IN COMPLEX RENO URETERAL LITHIASIS

GASPAR IBARLUZEA, MD.

*SIMULTANEOUS
ENDOUROLOGICAL ACCESS*

VALDIVIA MODIFIED GALDAKAO POSITION

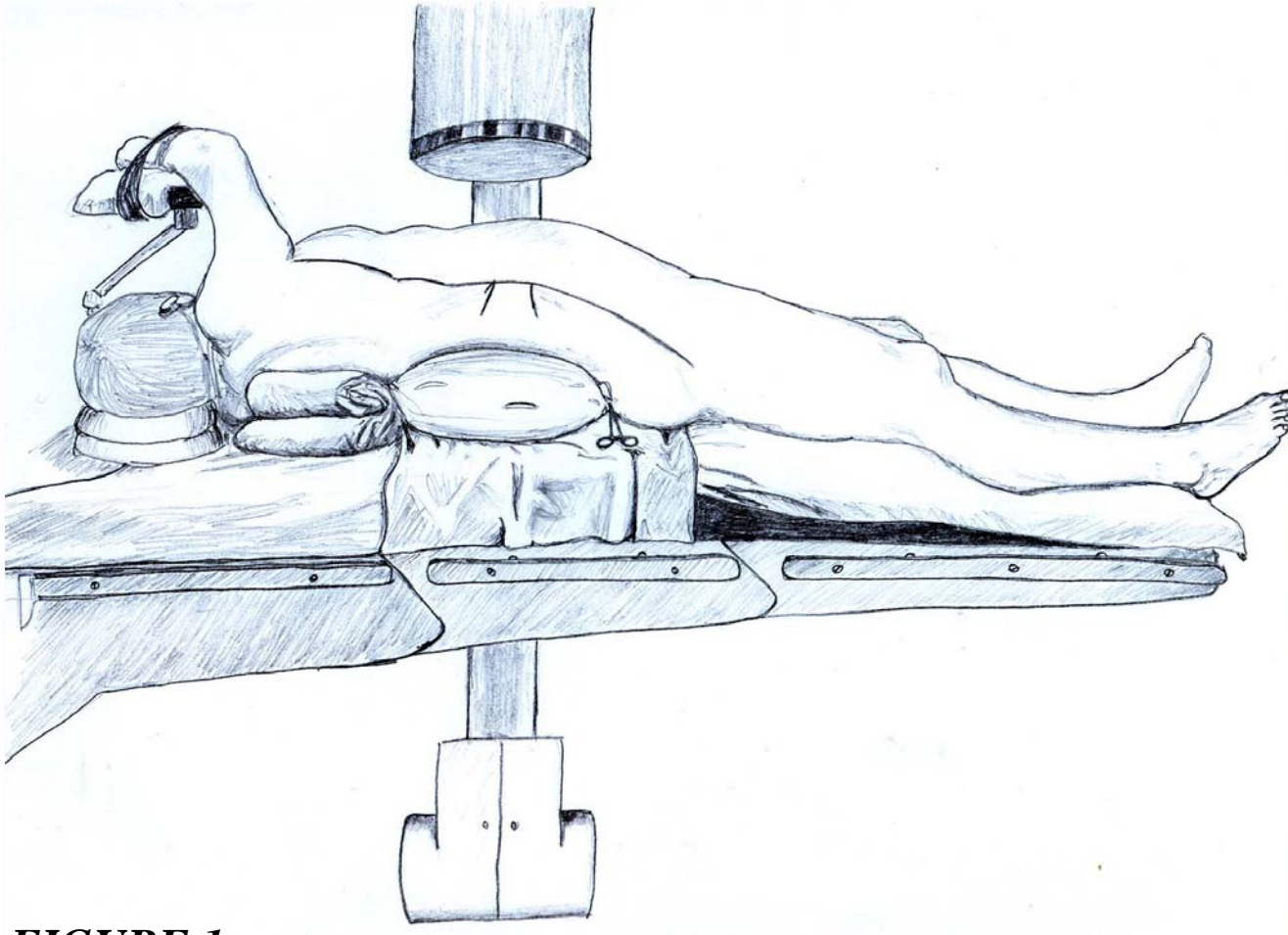


FIGURE 1:

Valdivia's position: supine position with air bag under the ipsilateral flank. A 3lt. saline irrigation bag filled with air and clamped with a Köcher clamp is used, this permits volume control until the most comfortable position is found.

This position has been used by us for over 1000 percutaneous nephrostomies over the past 16 years. It's safety and security have been demonstrated.

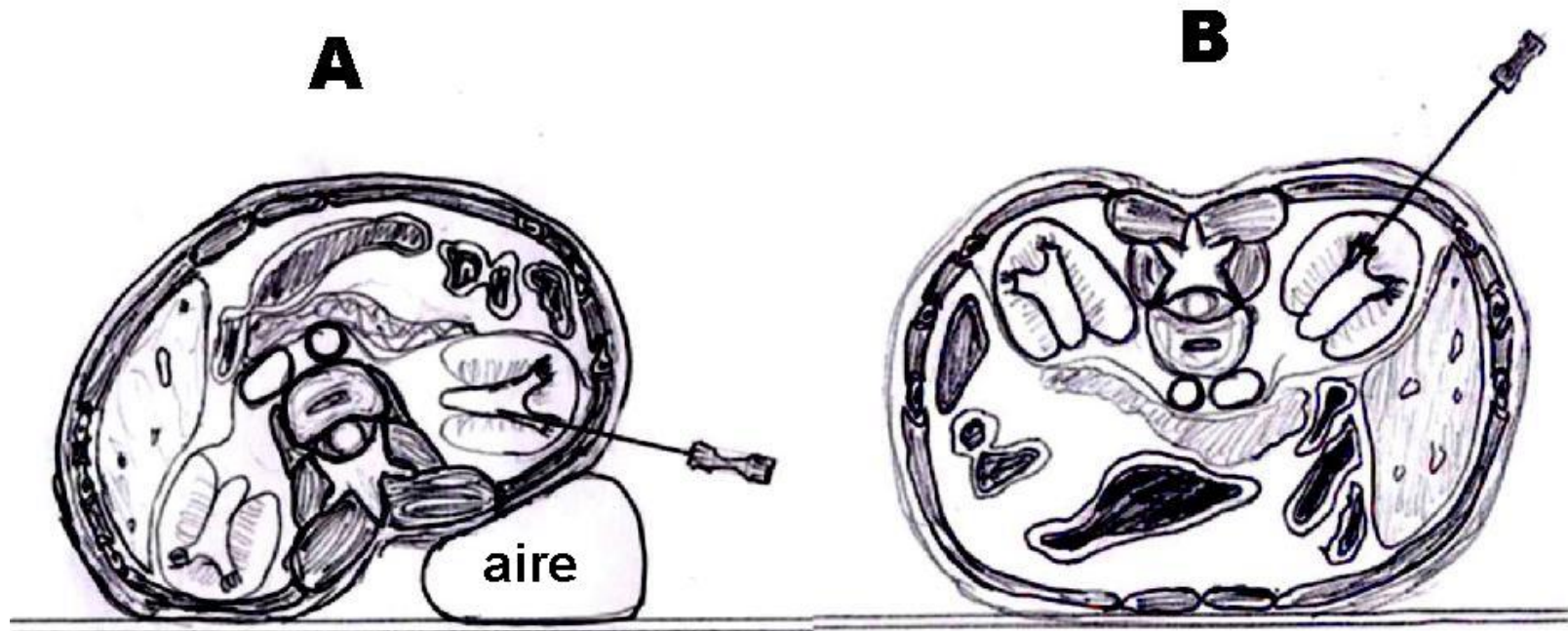
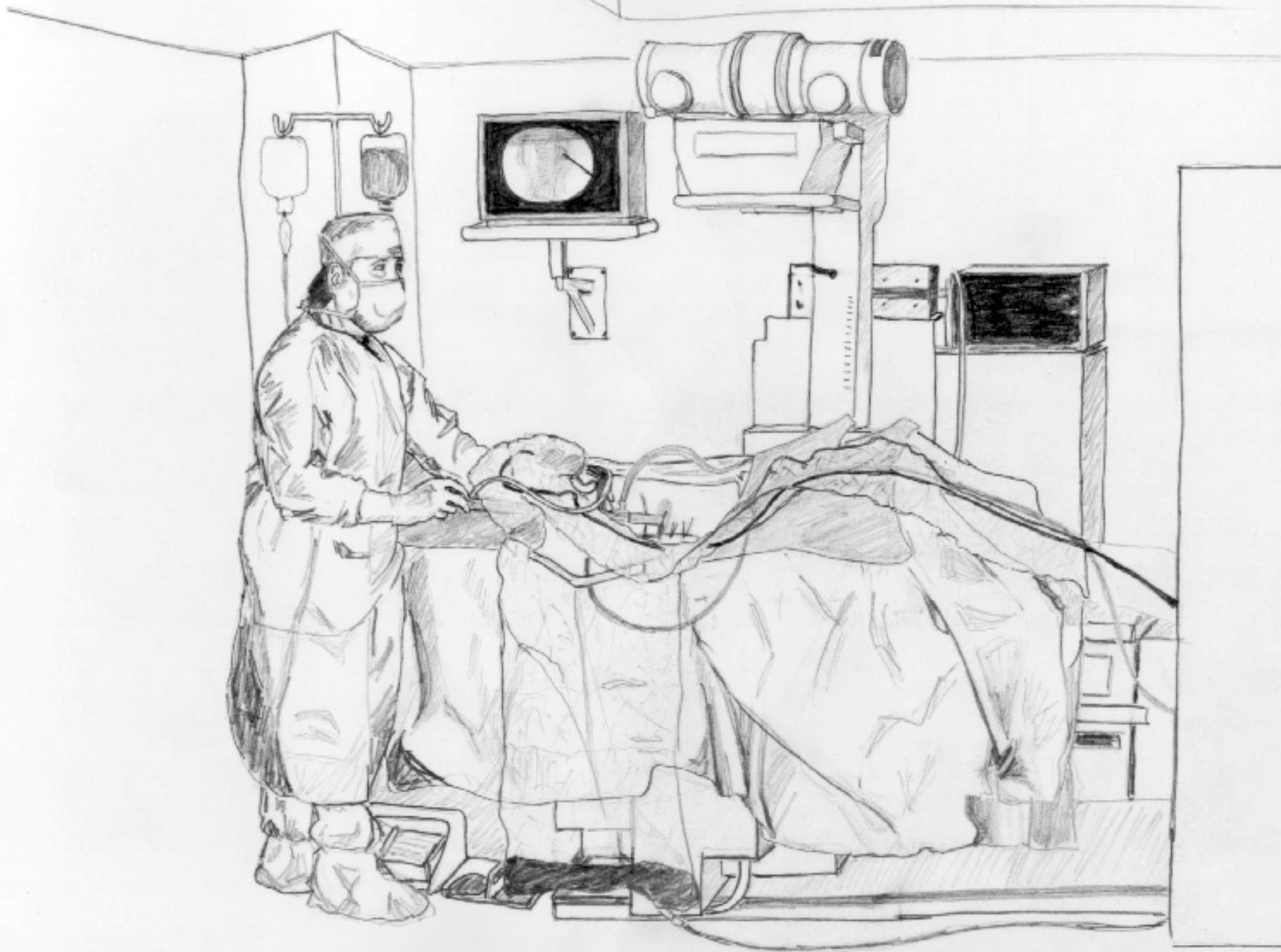


FIGURE 2:

- A. In Valdiva's position the direction of the needle goes slightly up , which may surprise us at first, when we change from the classic prone position to the supine.*
- B. In the traditional prone position the needle has an inclination of 45° with respect to the horizontal plane.*





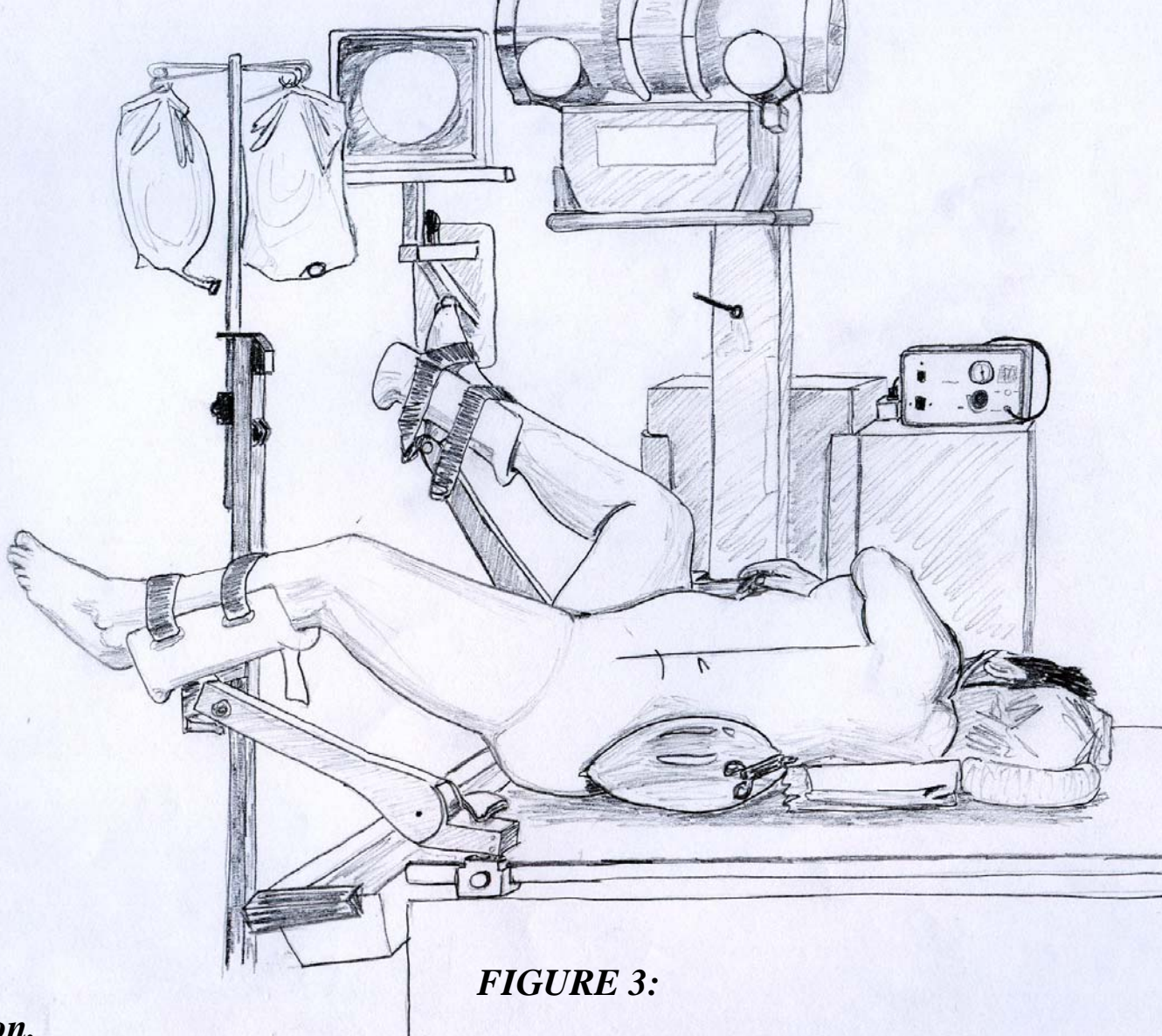


FIGURE 3:

Galdakao position.

For the resolution of complex endourological procedures, we have gradually adopted a new position which permits simultaneous transurethral access.

The ipsilateral leg is placed with minimal inflection and abduction and the contralateral leg is inflected and somewhat abducted.

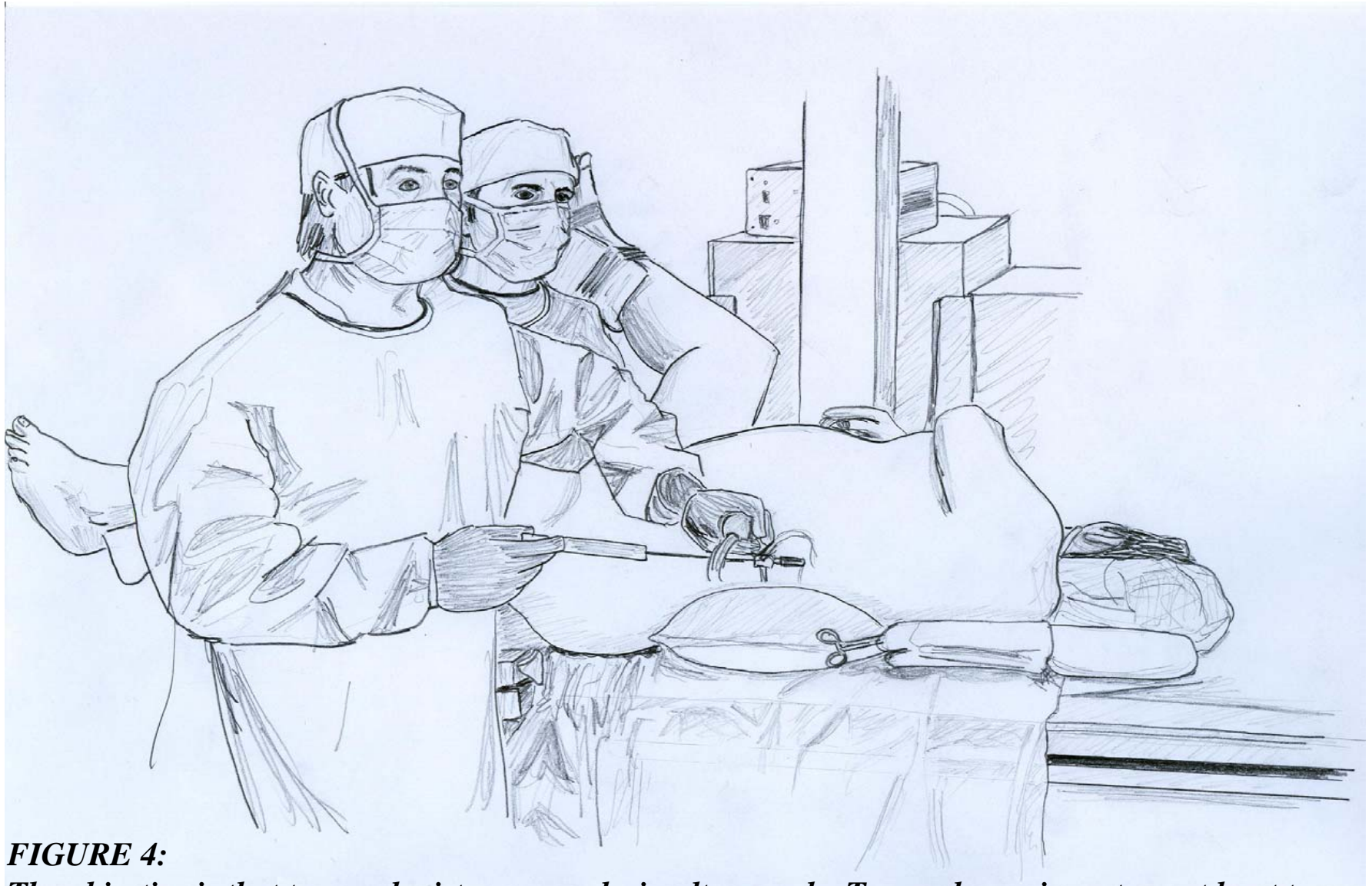

FIGURE 4:

The objective is that two urologists may work simultaneously. Two endoscopic carts or at least two light sources are required.

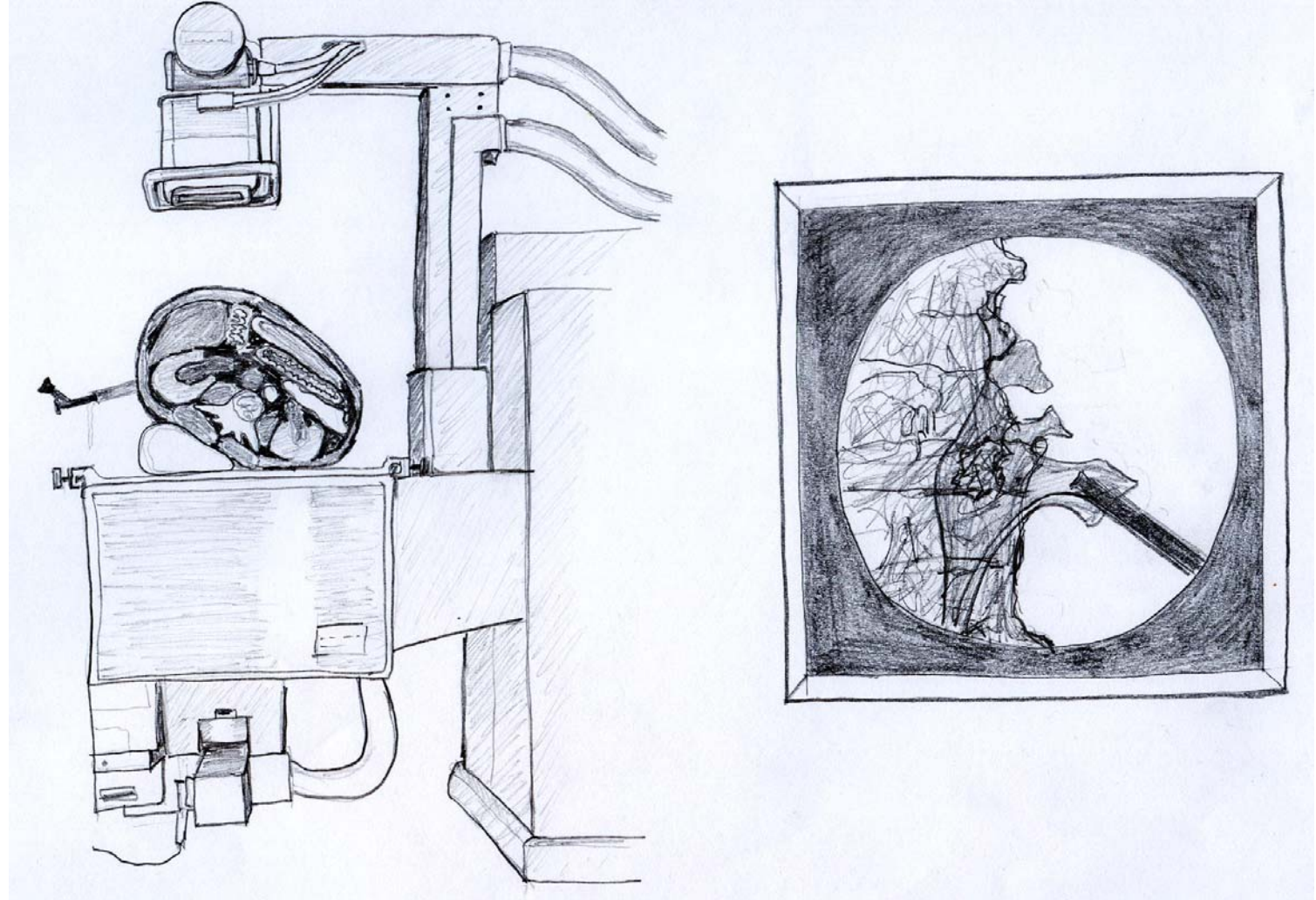


FIGURE 5:

Fluoroscopic tables from the 1980's, used specifically for endourology, present problems for this technique.

The patient can only be reached from one side and the x-ray projection is anteroposterior only, with which the kidney is on top of the backbone, difficulting the vision.

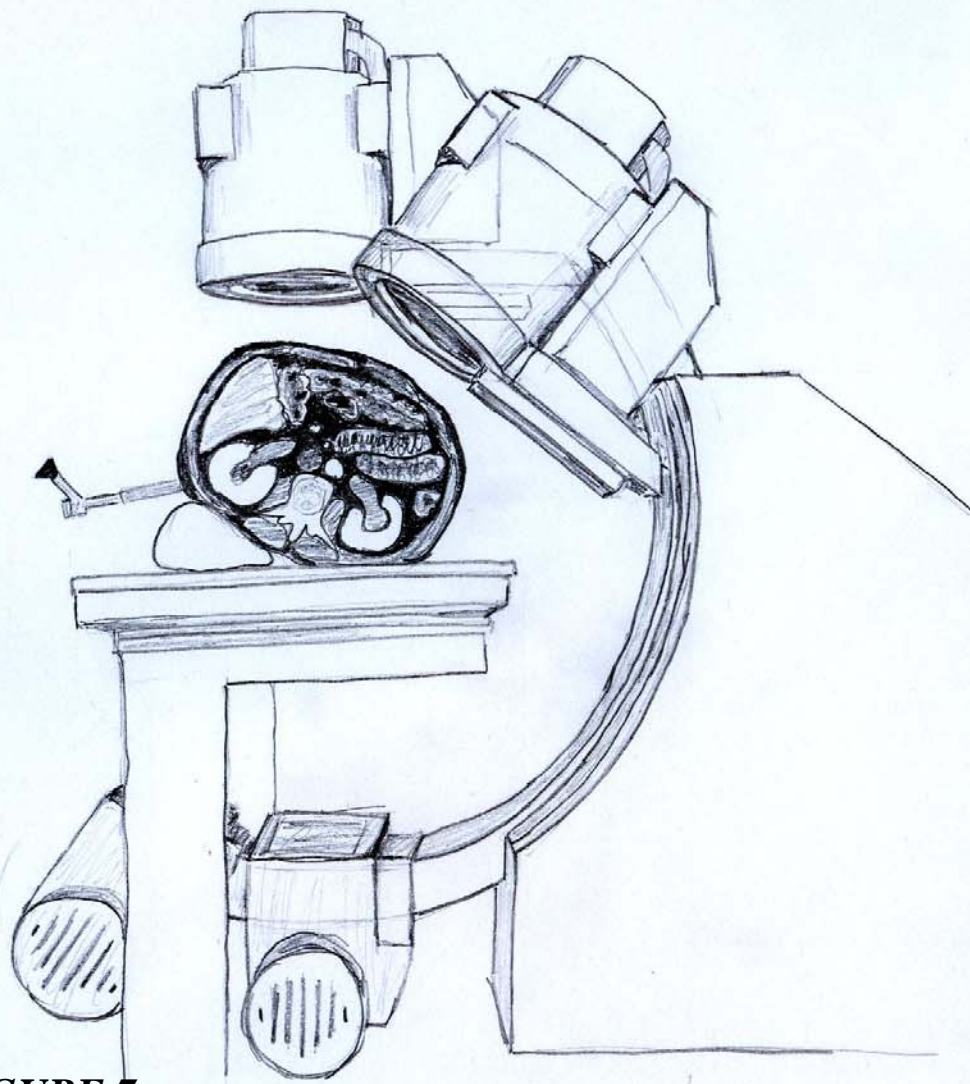
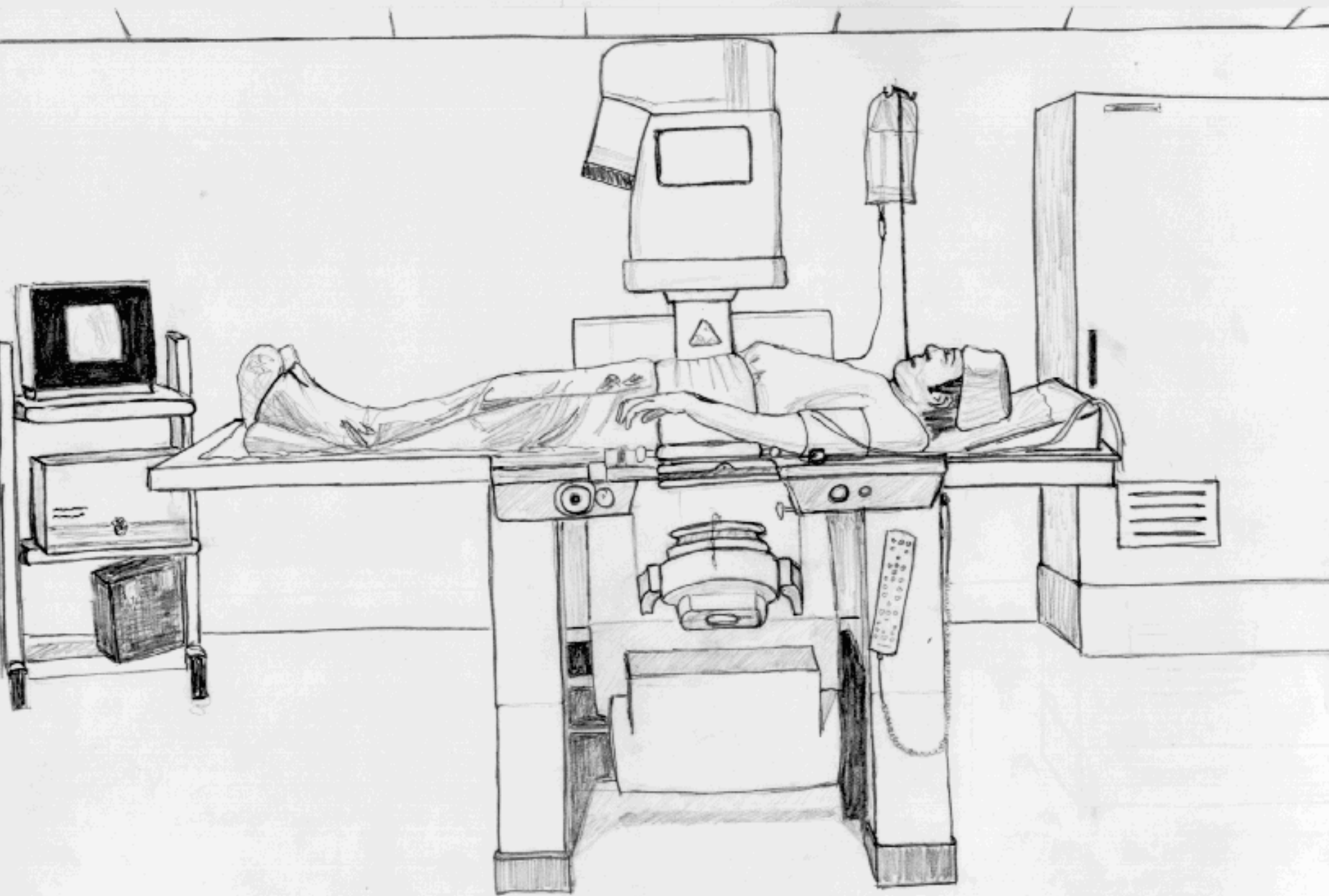


FIGURE 7:

The rotational C-arm fluoroscopy unit permits anteroposterior projection of the abdomen, with which a perfect position is achieved.

The majority of modern extracorporeal shock wave lithotripsy tables come fitted with rotational C-arm fluoroscopy units, which thus permit the most complex endourological procedures.



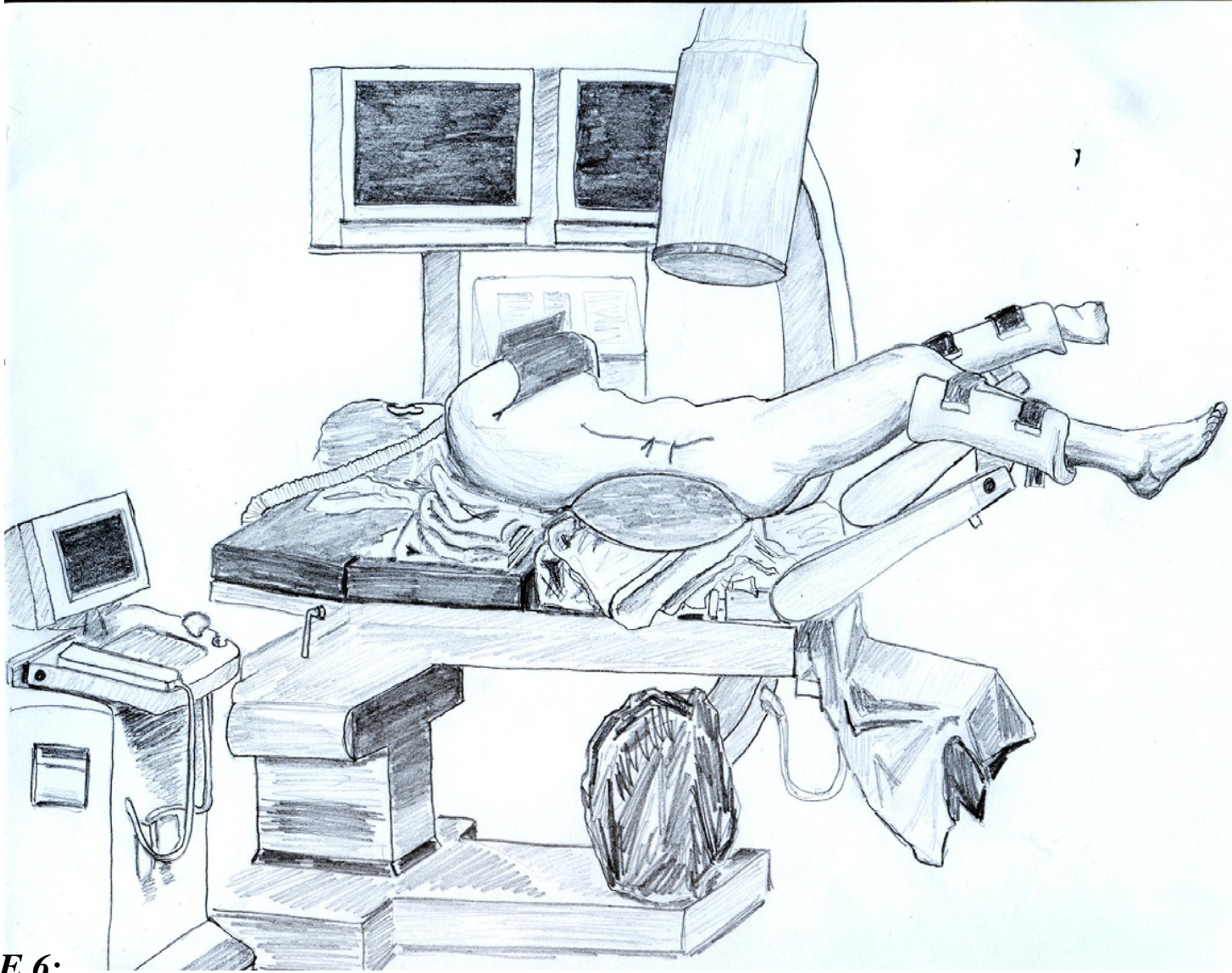


FIGURE 6:

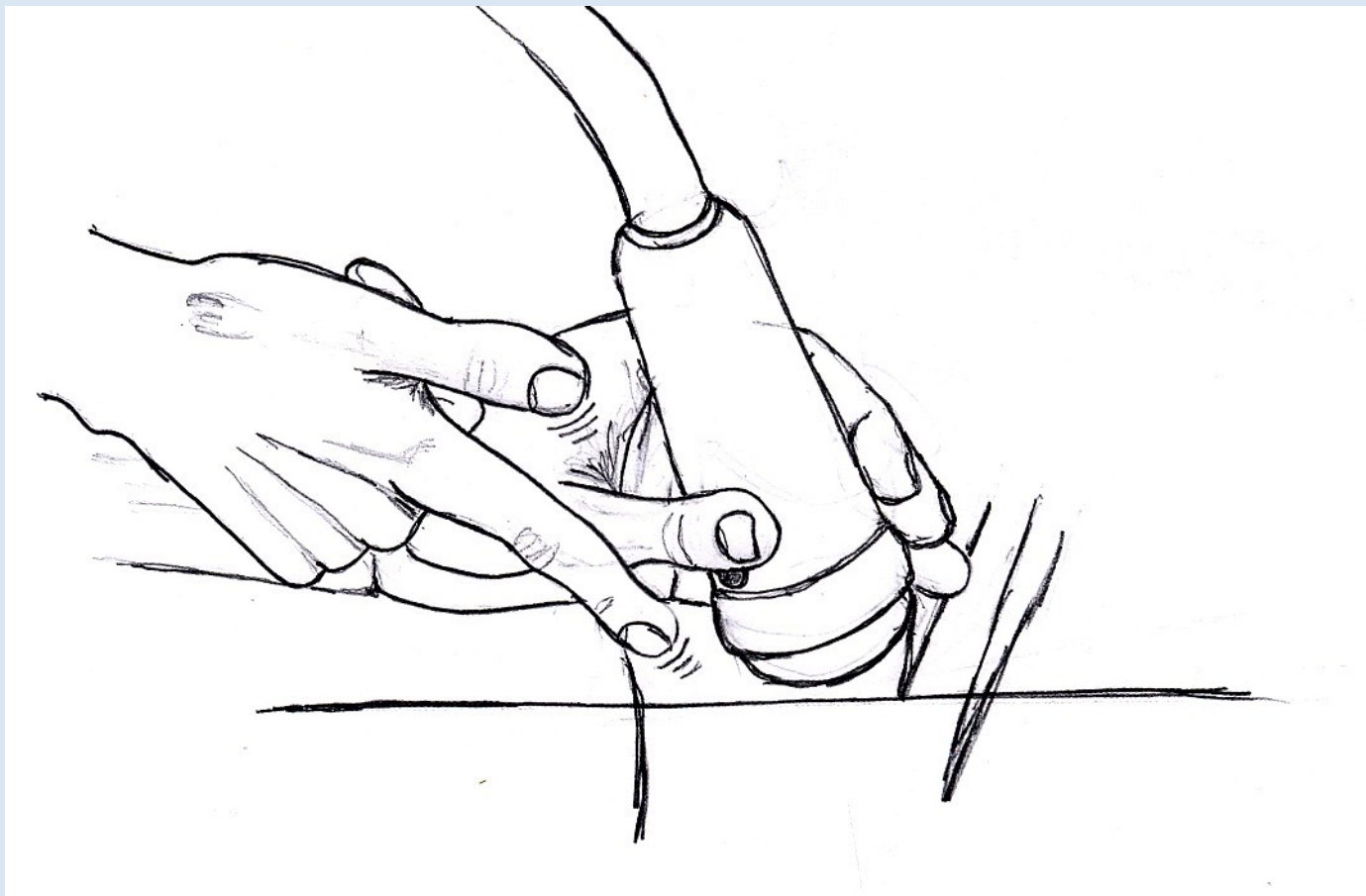
A conventional operating room with a radiolucent table and rotational C-arm fluoroscopy unit is the ideal place for the practice of this procedure.

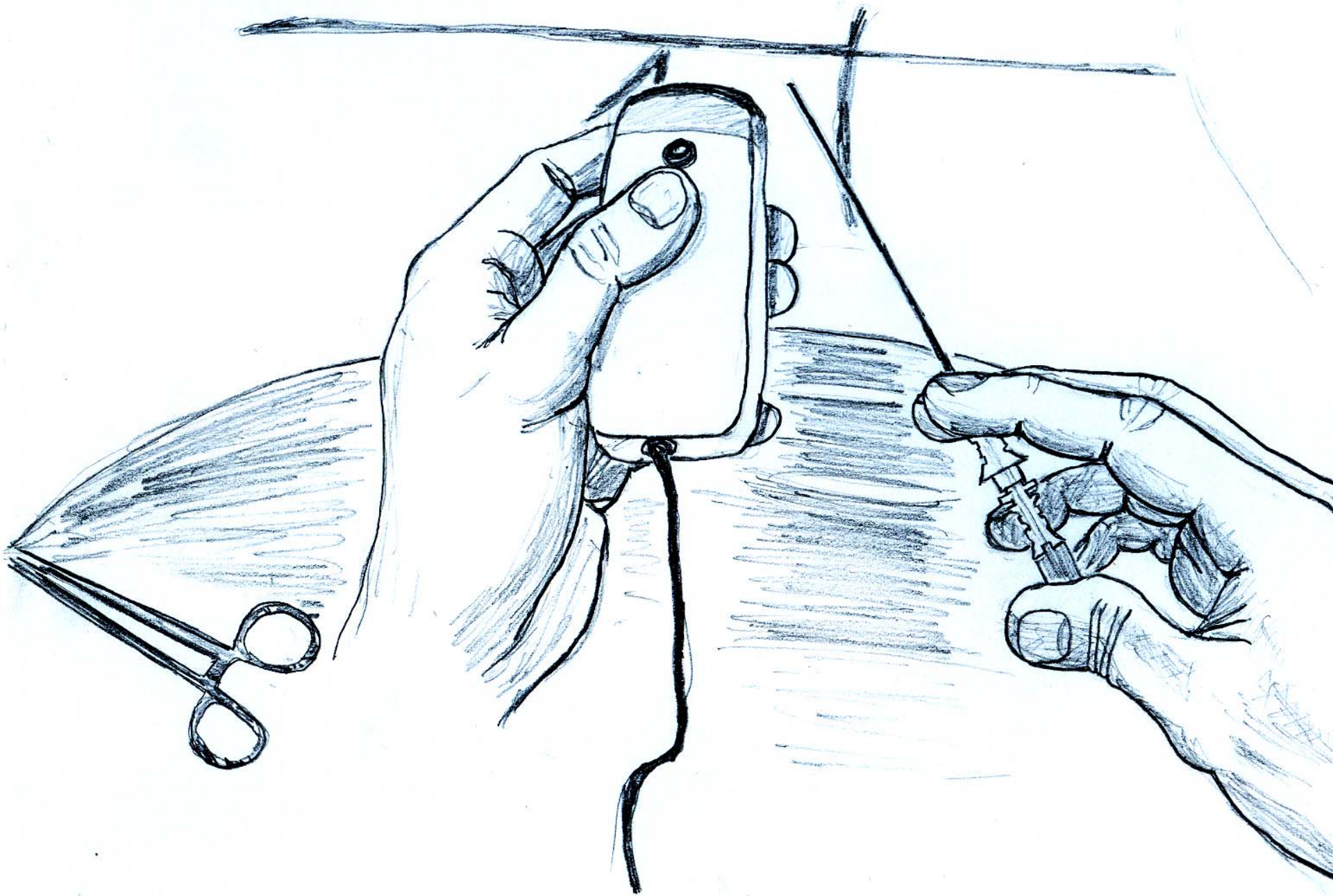
It is advisable to draw the reference lines on the skin before positioning the air bag.

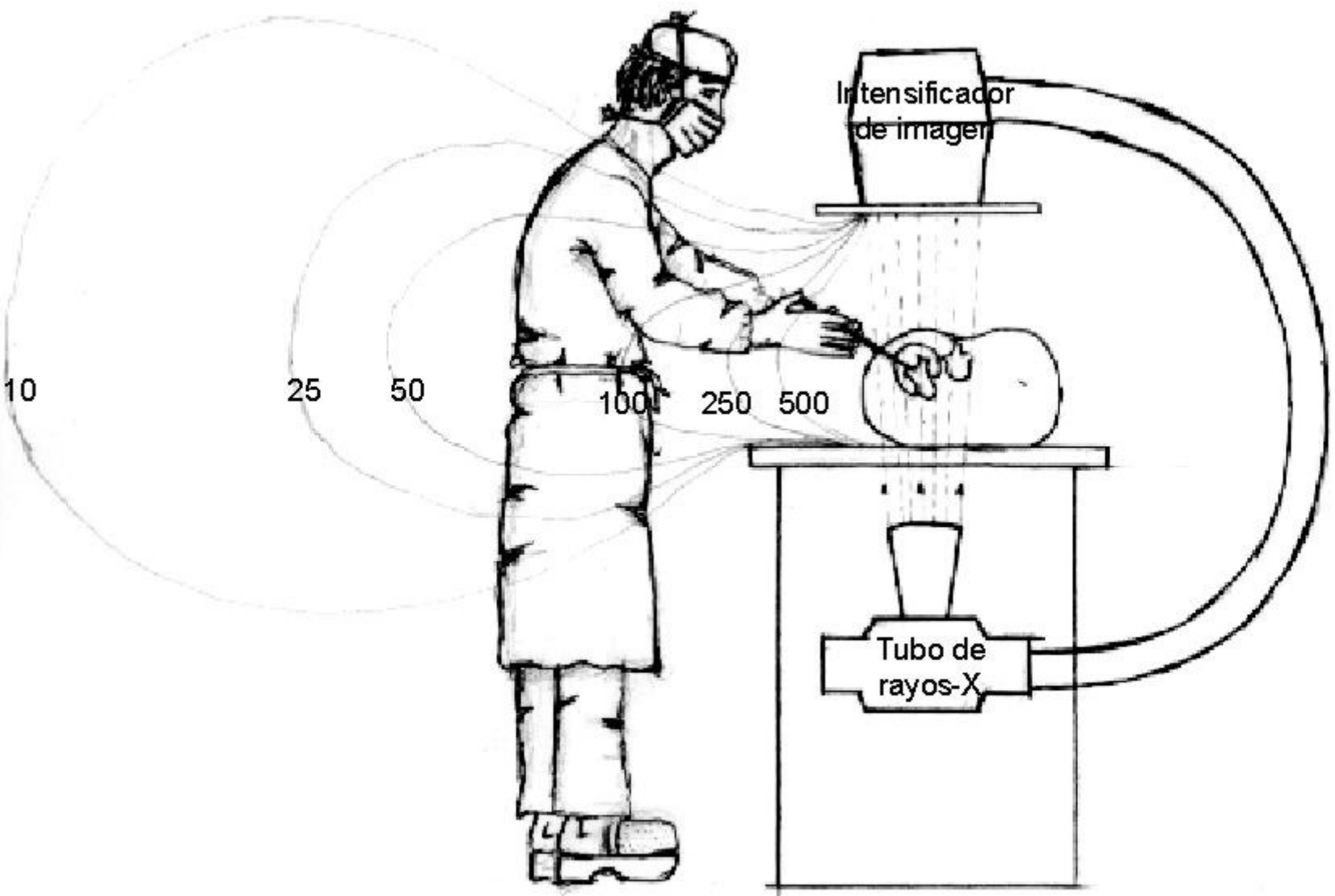
Barcelona

25th Anniversary EAU Congress

16-20 April 2010







Intensificador
de imagen

Tubo de
rayos-X

10

25

50

100

250

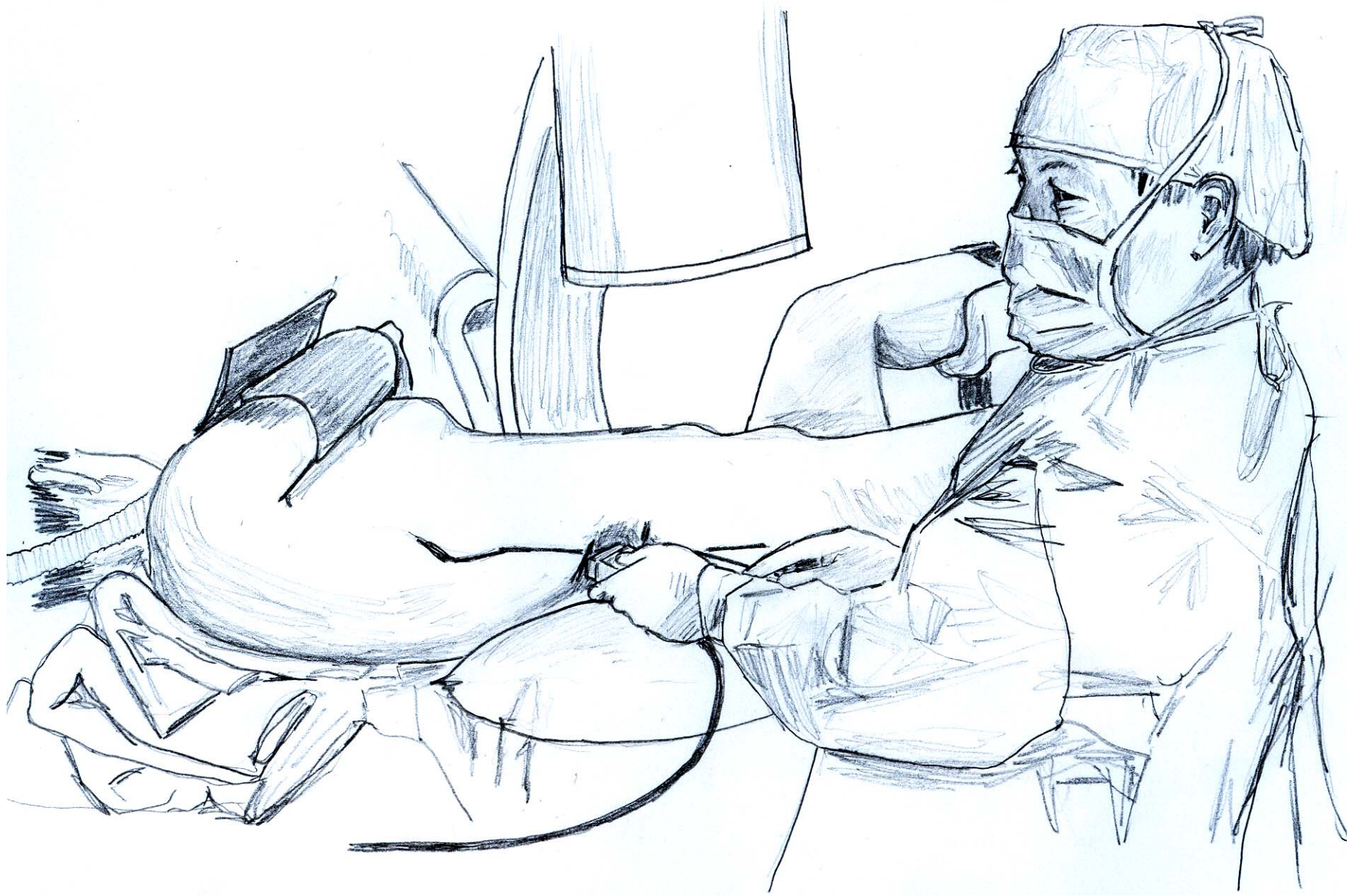
500



FIGURE 8:

The percutaneous puncture must be made as close as possible to the posterior axillary line without crossing it ventrally.

The direction of the needle rises slightly as we look at it horizontally and is directed in search of the desired calix, normally the lower one.



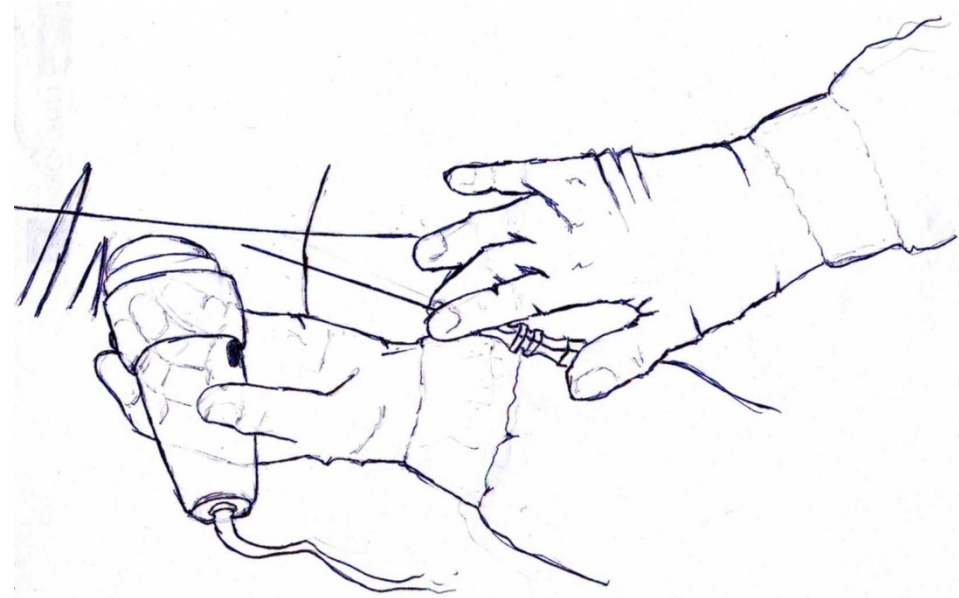
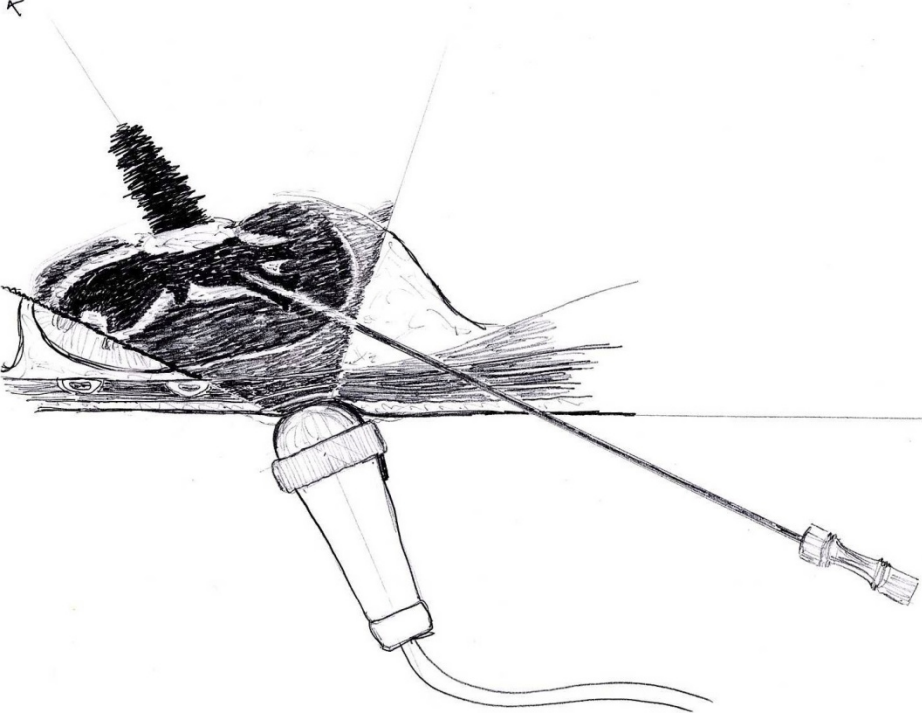


FIGURE 9:

The “freehand” ecoguided percutaneous puncture allows us to direct the needle at the most appropriate angle. The trick is to go after the ultrasonic beam with the needle.

It is the safest procedure since it permits the control of the structures located between the skin and the kidney.

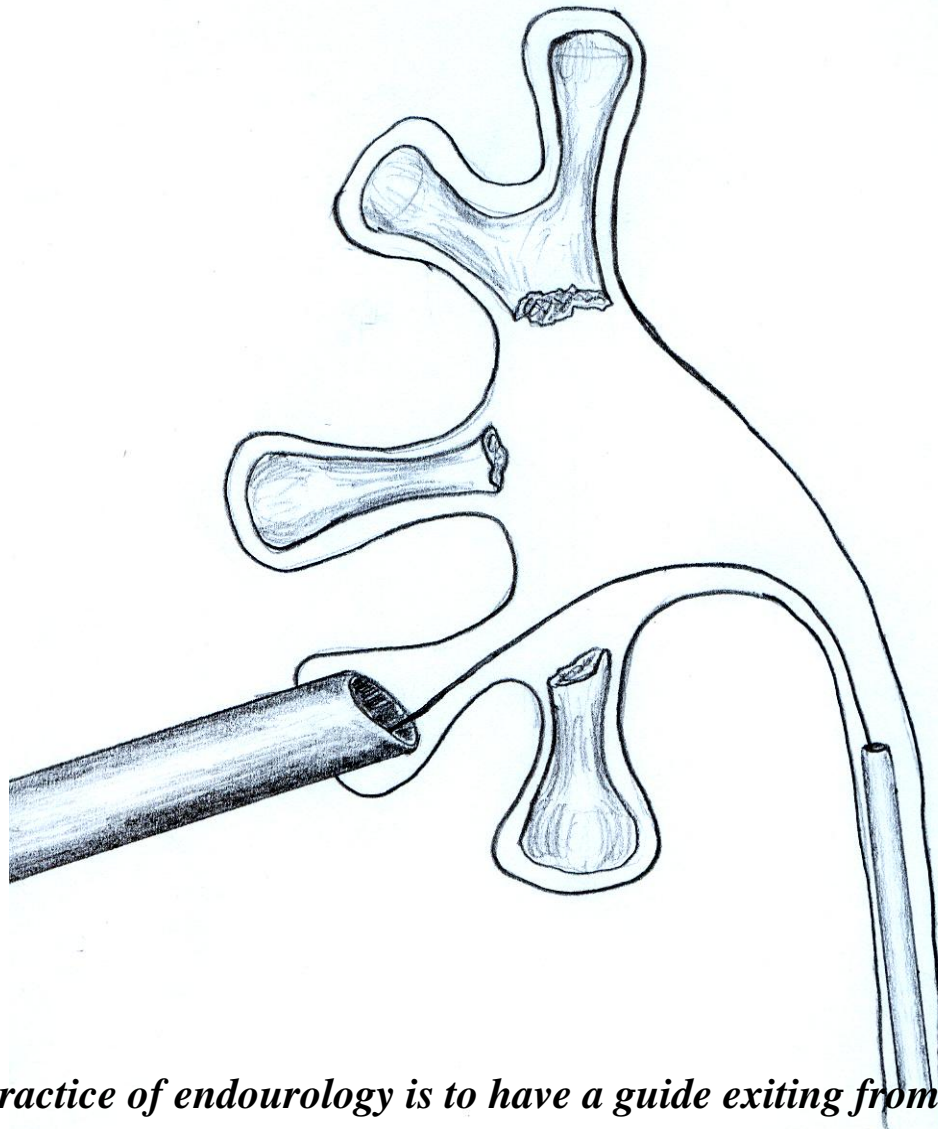
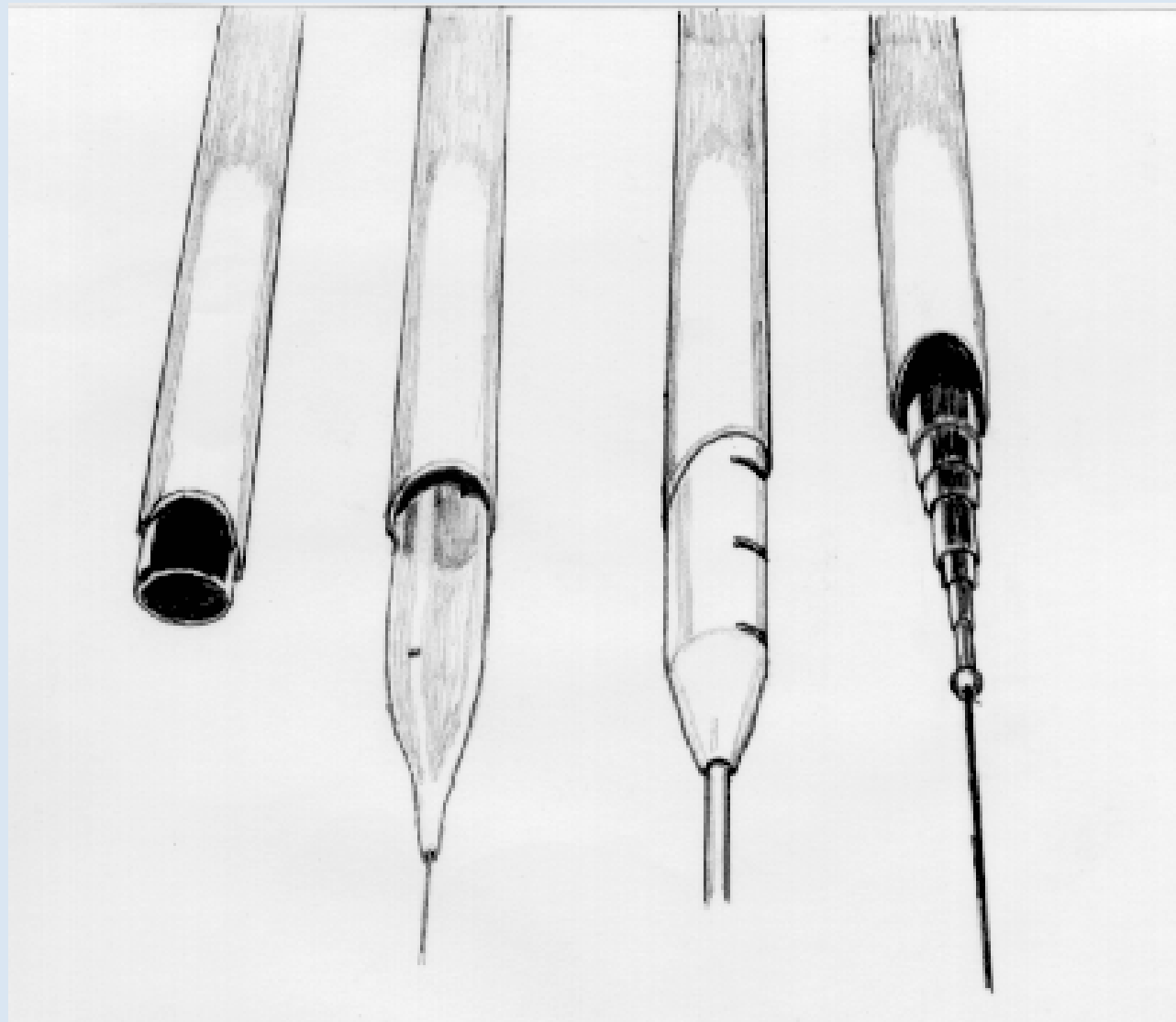


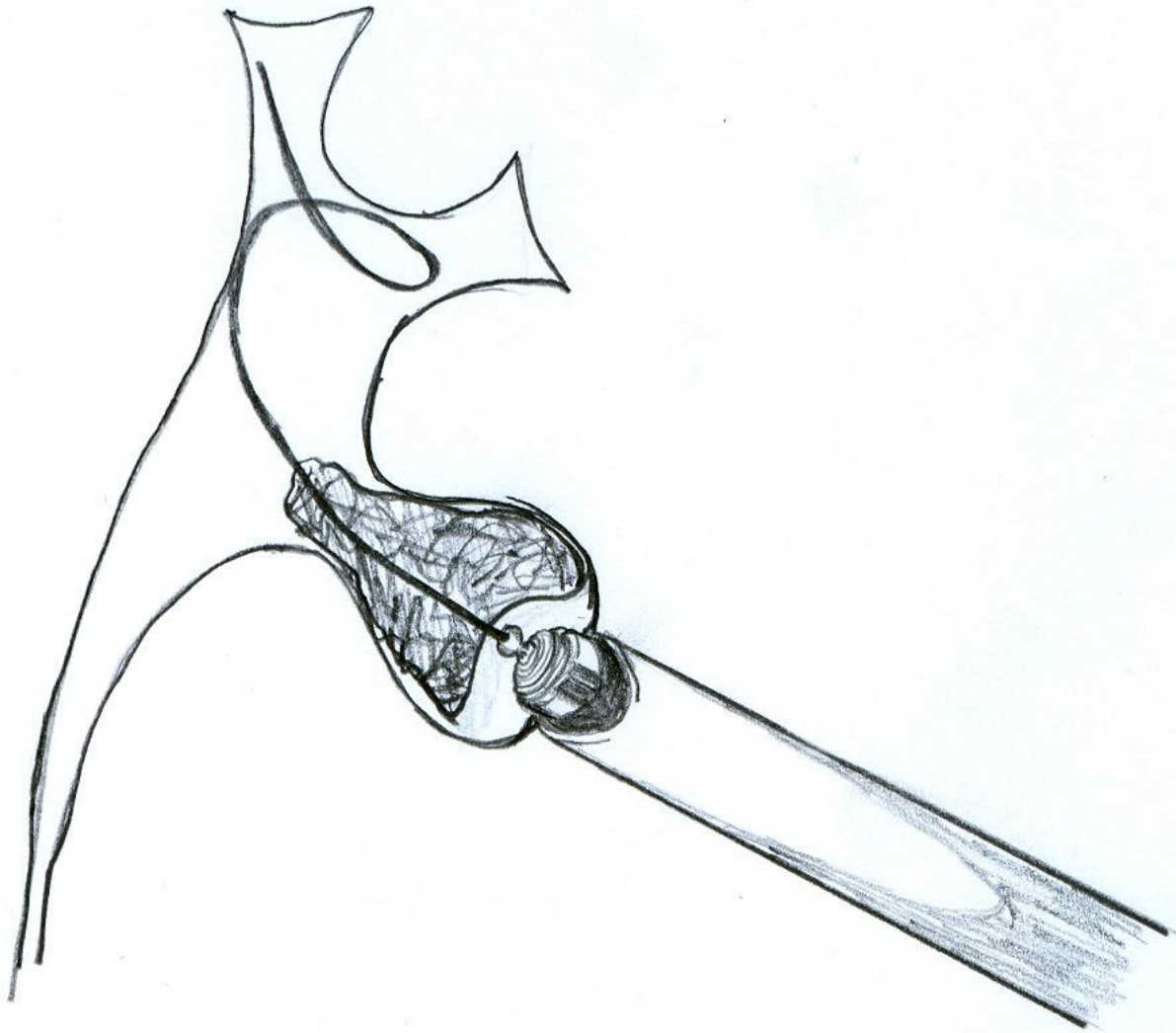
FIGURE 10:

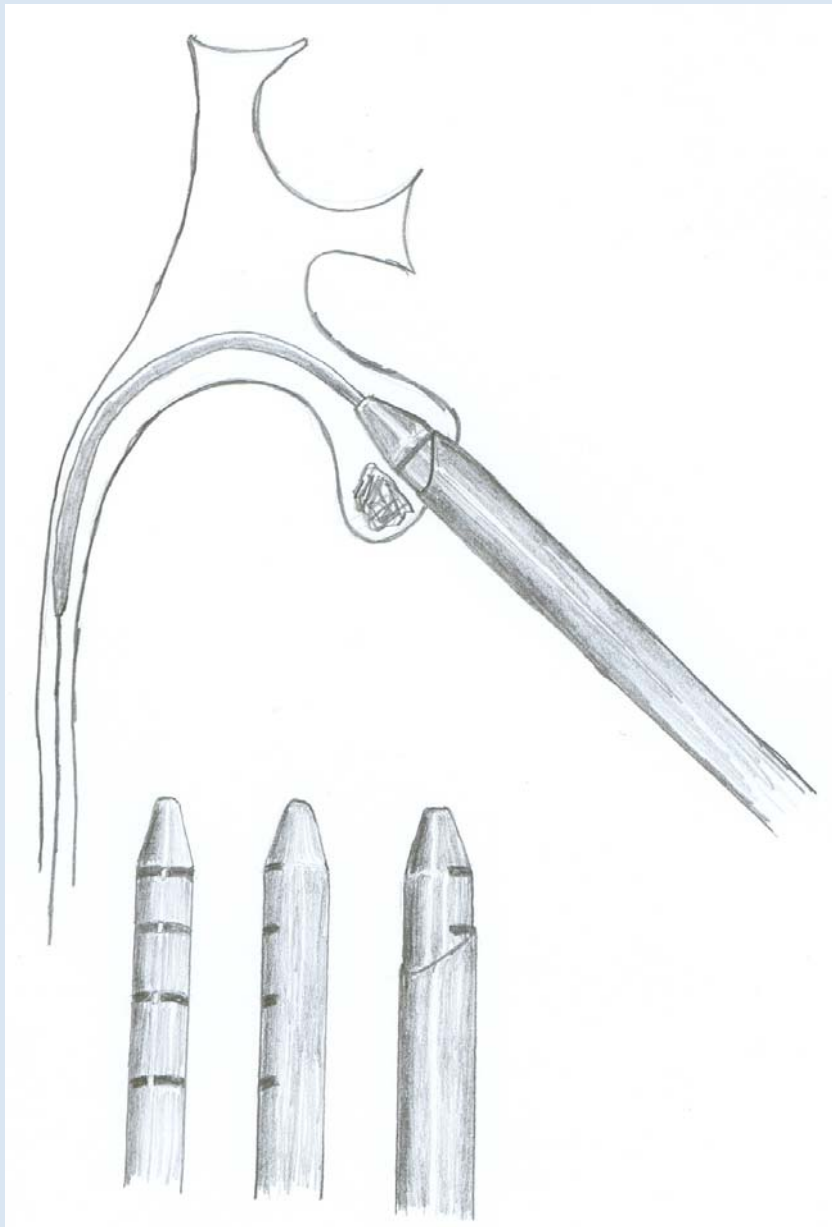
The safest setup for the practice of endourology is to have a guide exiting from both the skin and the urethra.

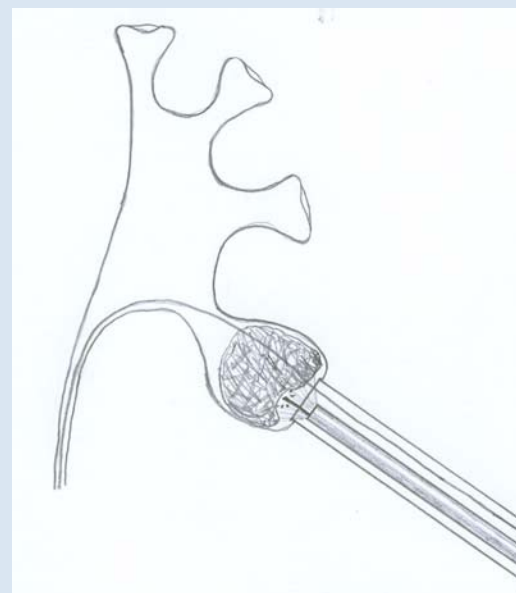
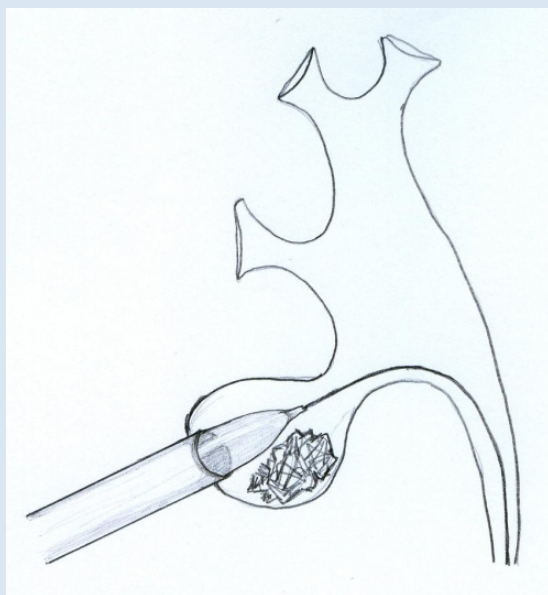
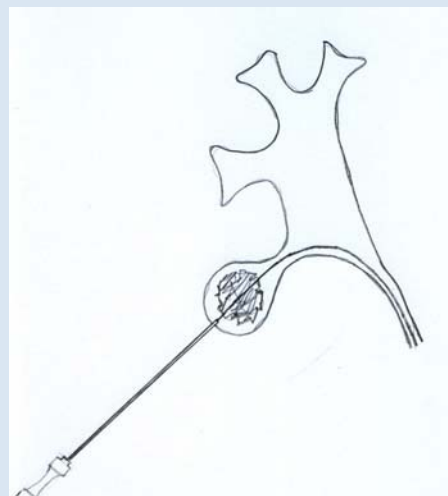
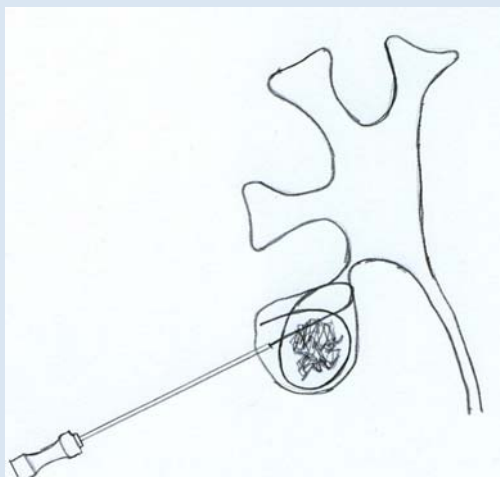
This technique is especially useful in the treatment of complex renal lithiasis through just one percutaneous access point through the lower calix.

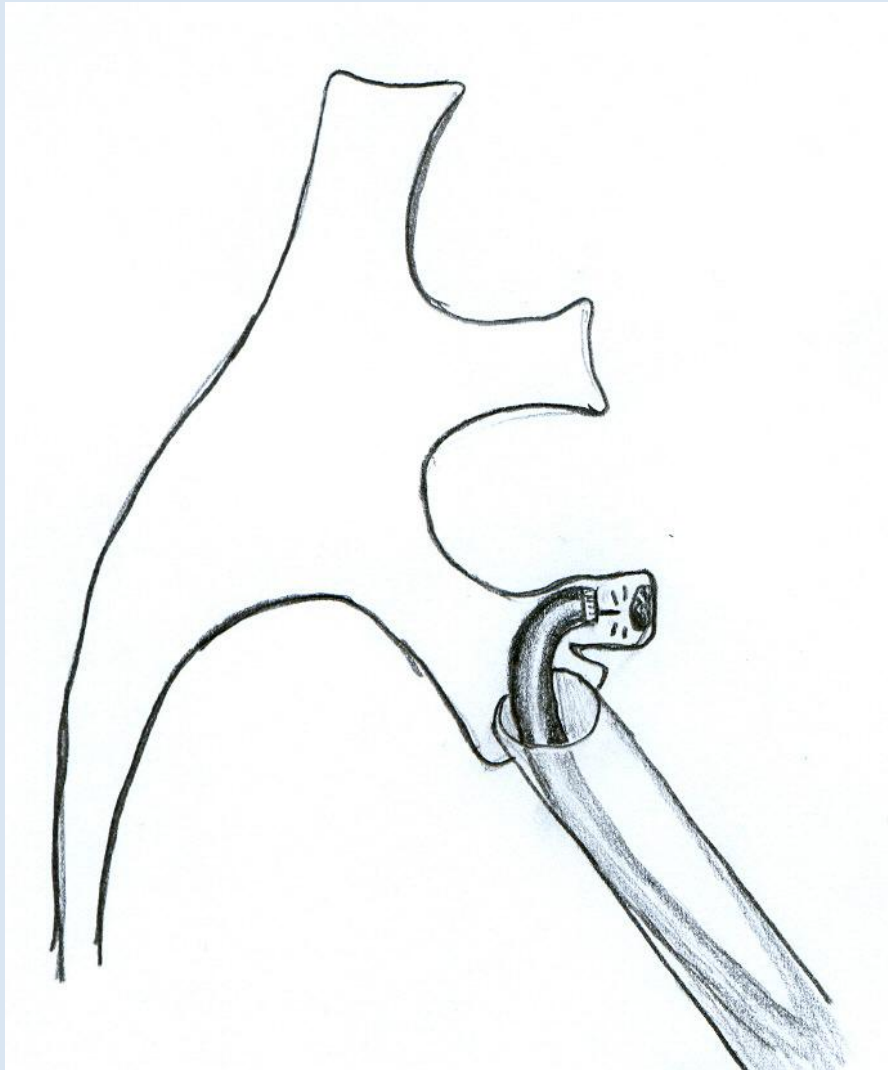


Barcelona
25th Anniversary EAU Congress
16-20 April 2010









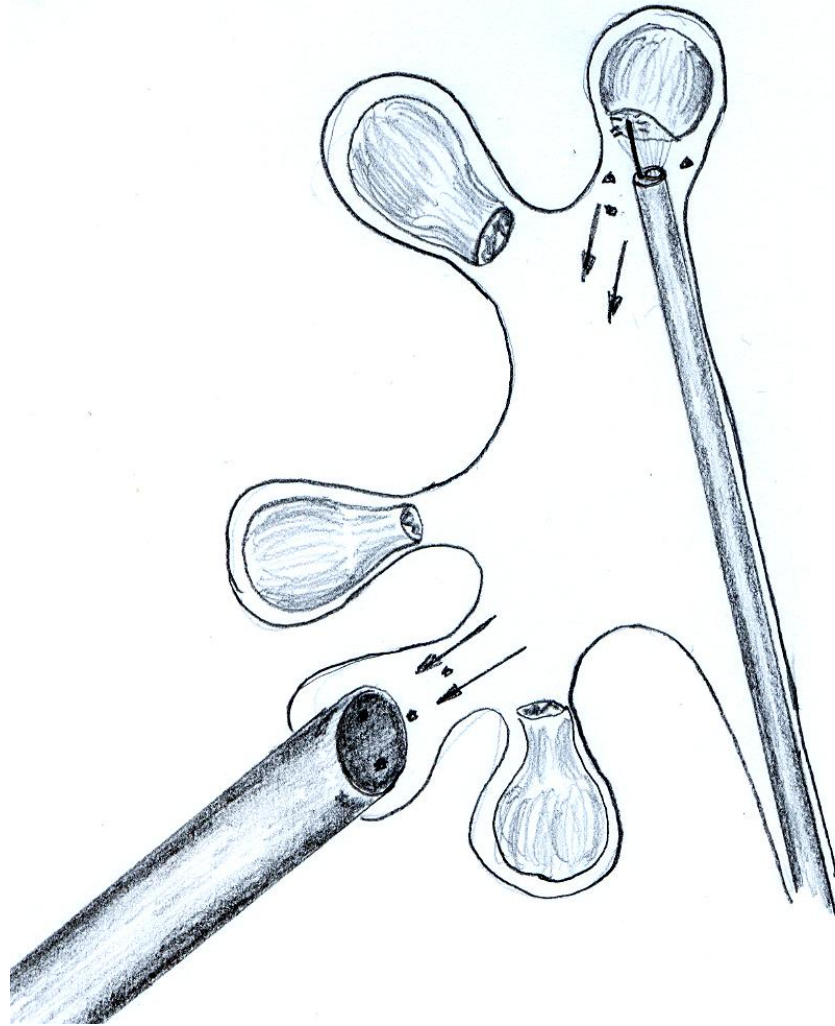


FIGURE 11:

Treatment of complex renoureteral lithiasis. Transurethral rigid instruments can be used for upper pole litotripsy after solution of ureteral calculi.

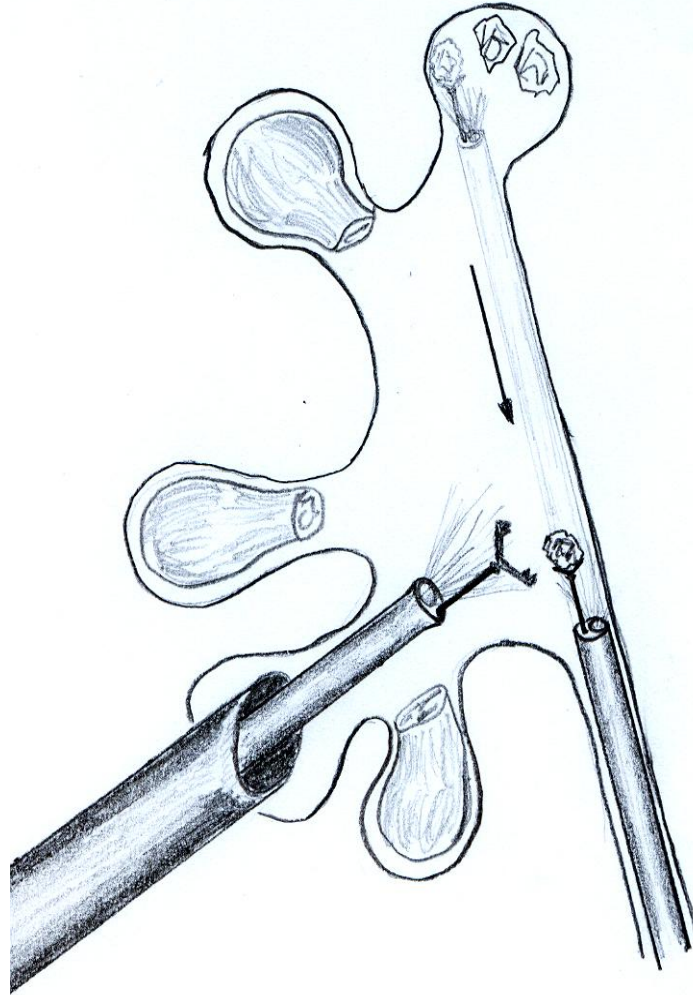


FIGURE 12:
Taking advantage of the Amplatz sheath to evacuate fragments by the fastest and easiest route.

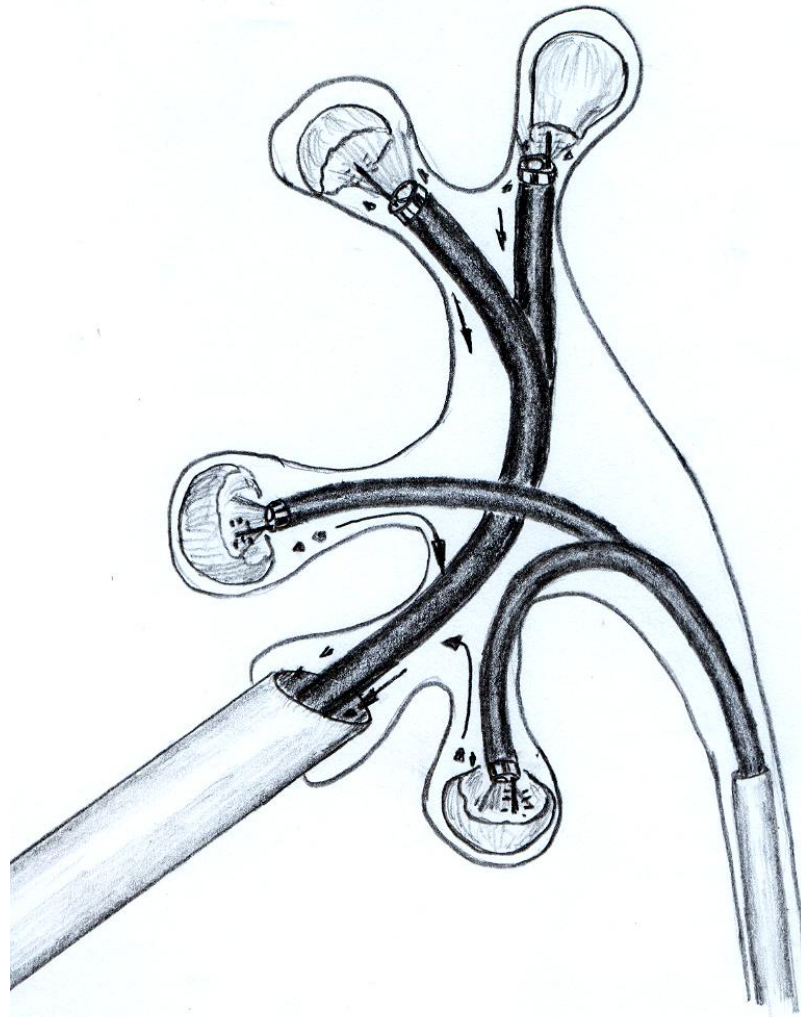
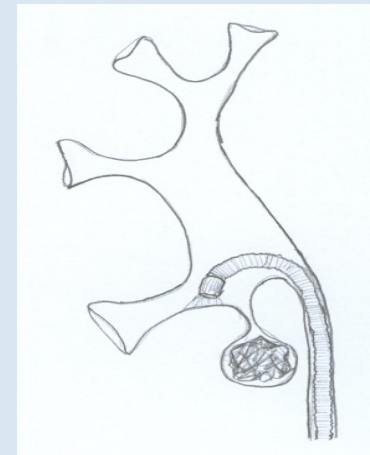
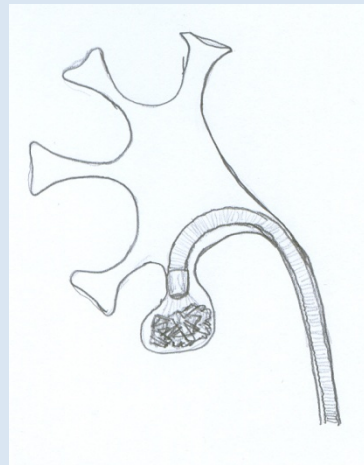
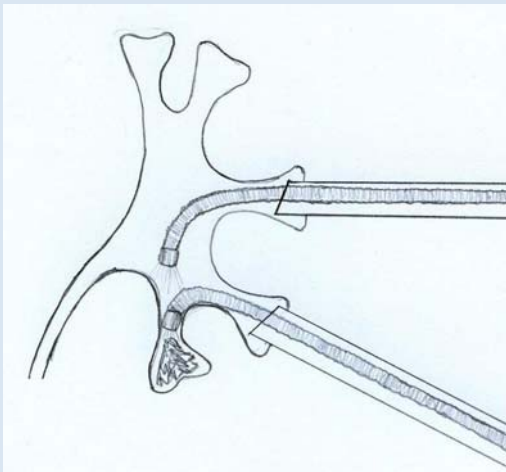
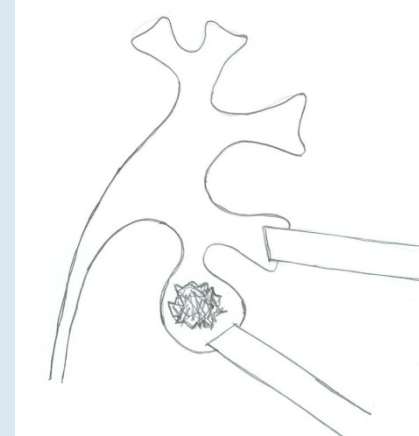
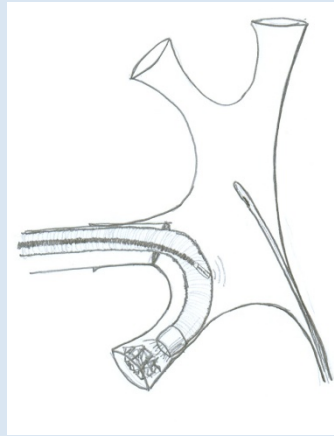
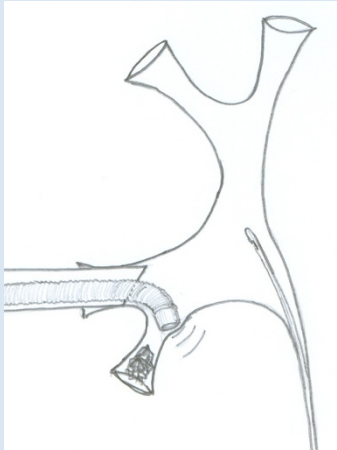
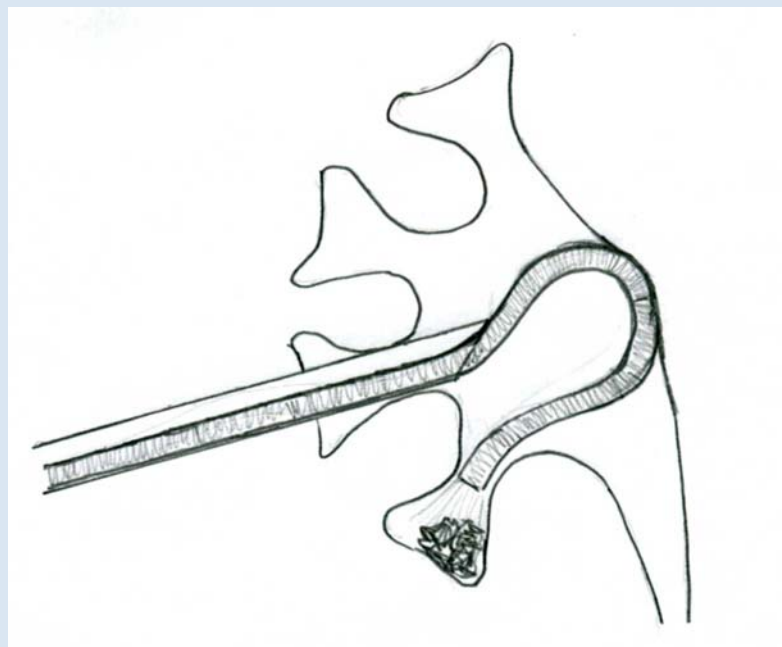
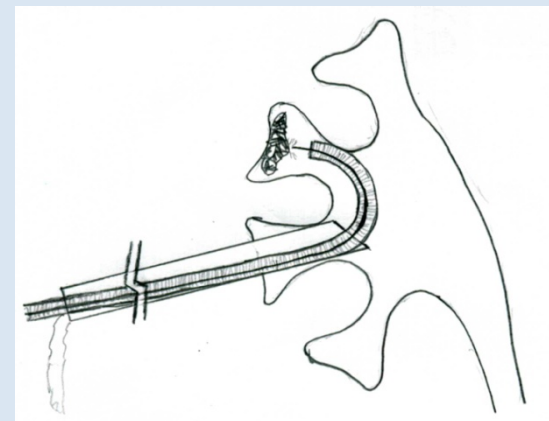
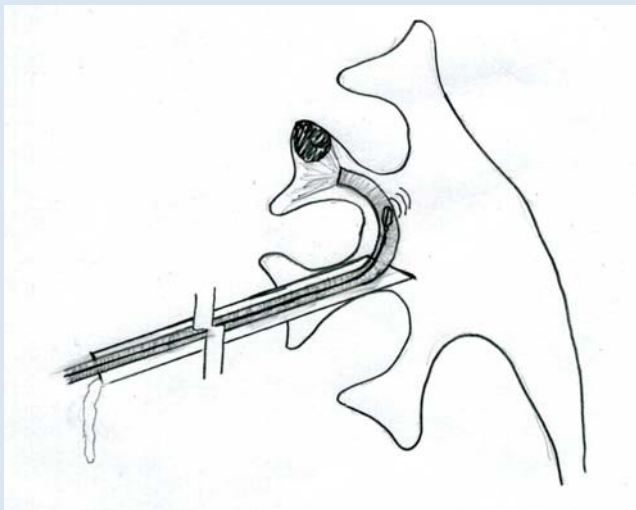


FIGURE 13:

With flexible instrumentation and Holium laser, access to all parts of the urinary tract is possible. The Amplatz and urethral access sheaths allow us to work at low pressures. Ureteromat type irrigation fluid pumps must be used to stretch the urinary tract.

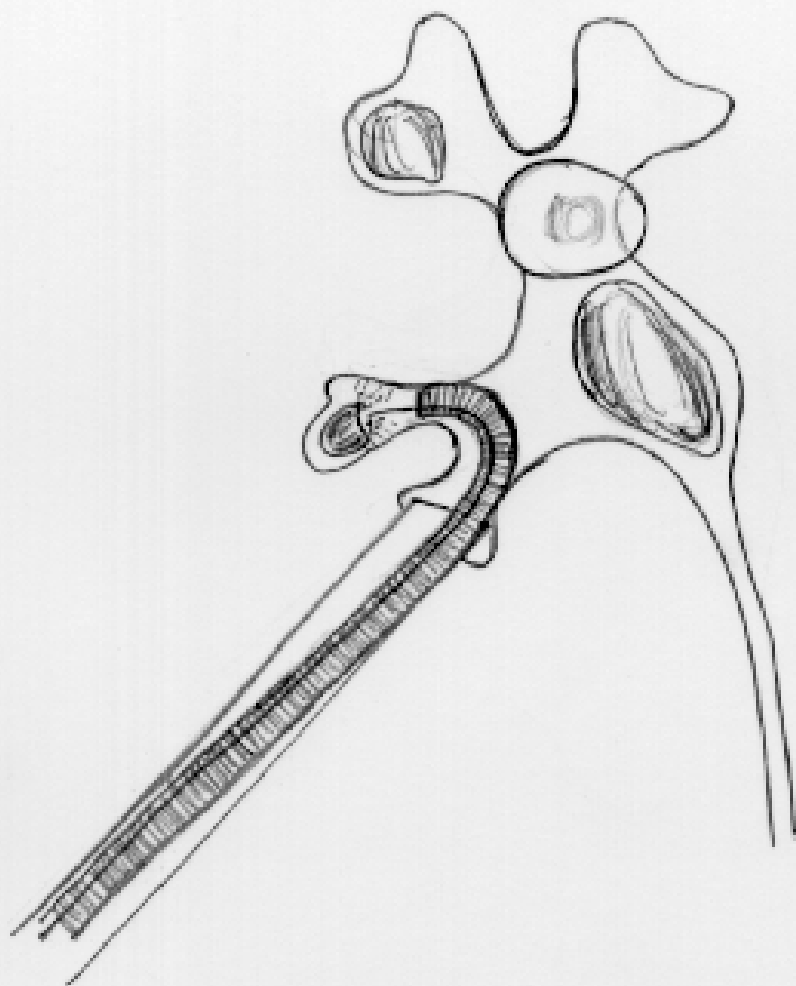




Barcelona

25th Anniversary EAU Congress

16-20 April 2010



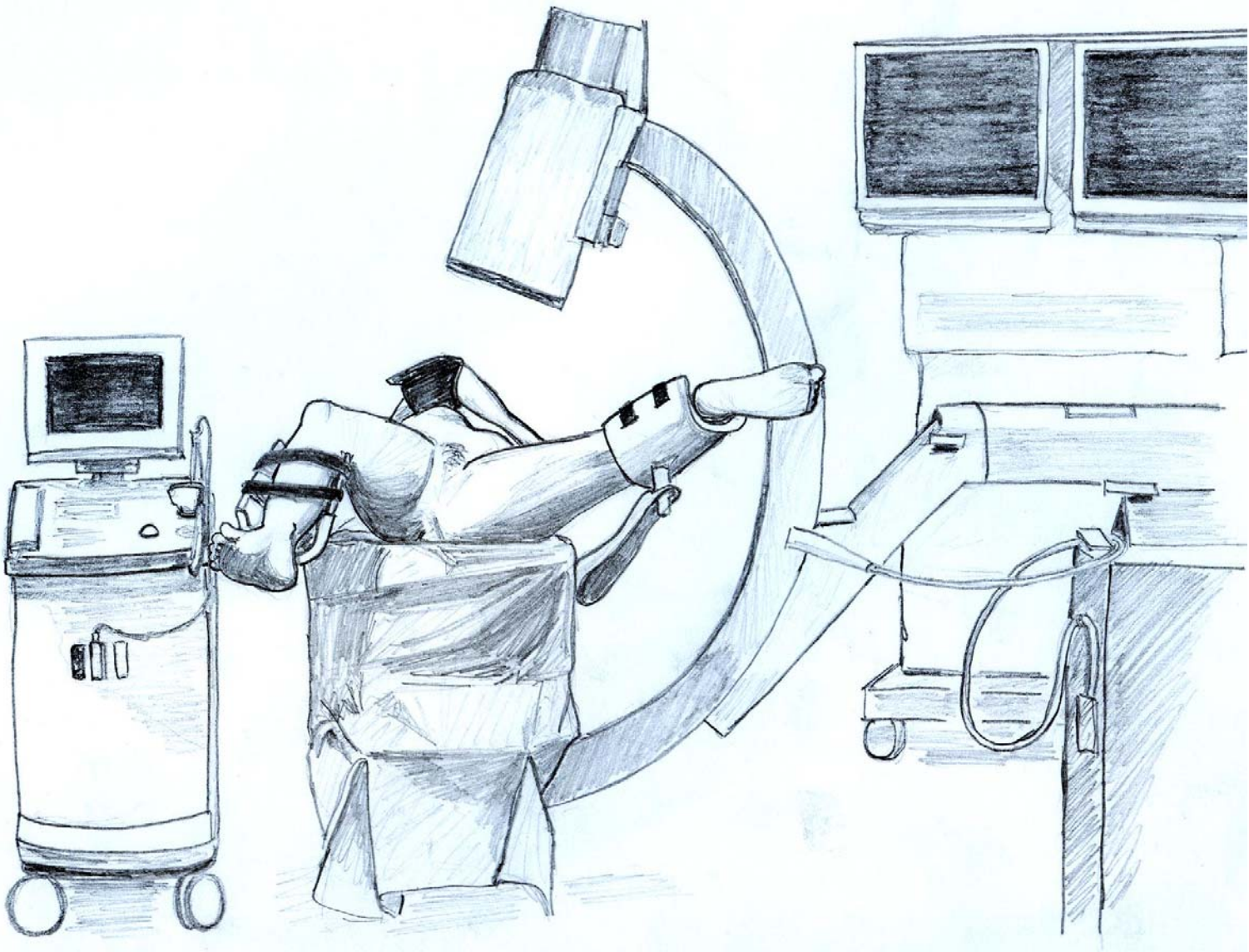
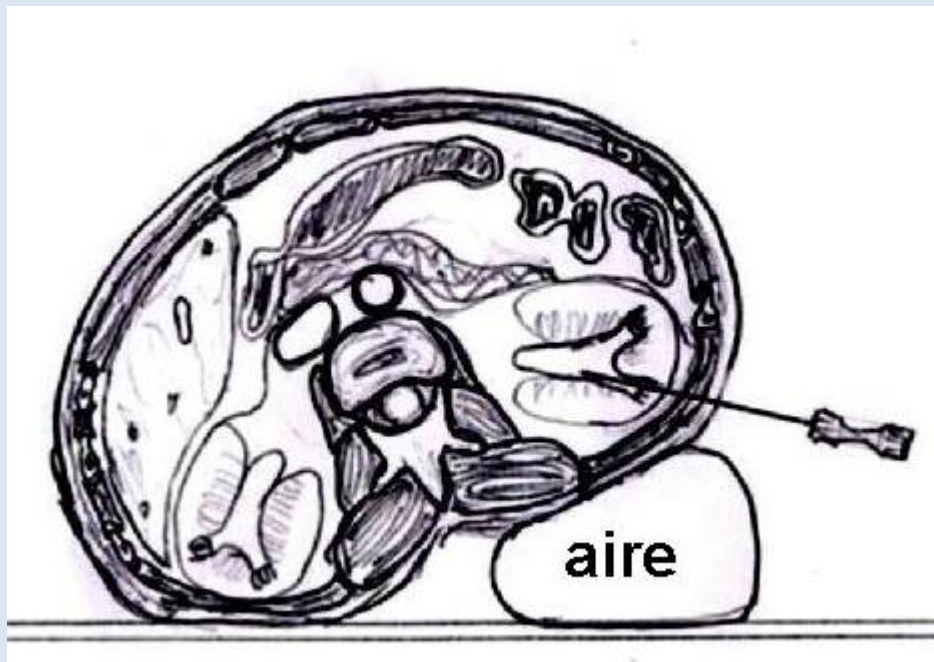


FIGURE 14:
Vision of the patient in the Galdakao position, seen from the transurethral access point. Clearly useful in ureterorenoscopies in which the need for a nephrostomy or a reversion to percutaneous renal surgery is foreseen.

Barcelona

25th Anniversary EAU Congress

16-20 April 2010



DRAFTMAN: MIKEL GAMARRA, MD.



EAU

European
Association
of Urology

©

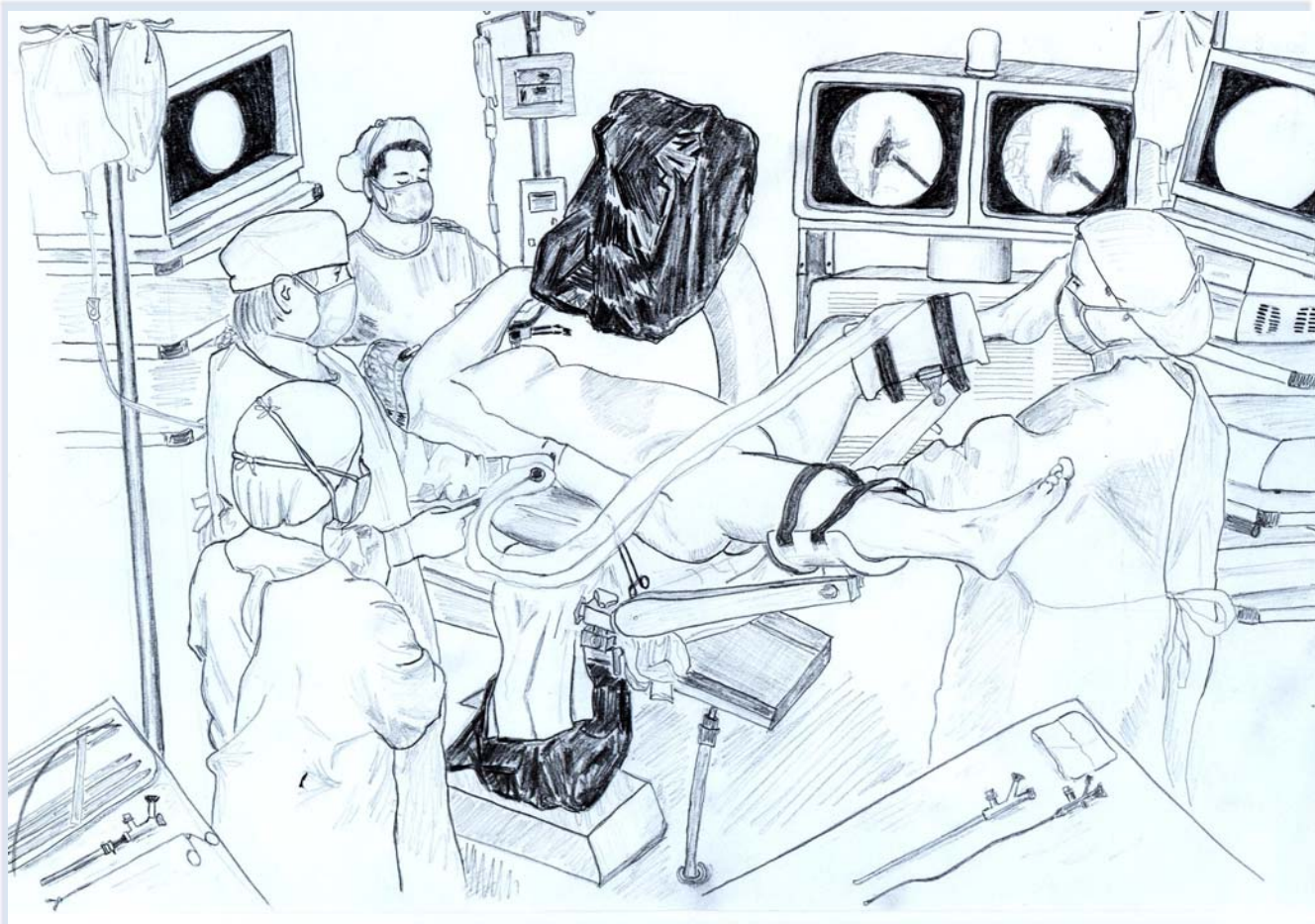


FIGURE 15:

General perspective of a complex endourological intervention.

The anaesthetist at the head of the patient is the one who is going to appreciate the position.

A nurse with two operative tables for NLP and URS.

Two urologists working simultaneously through both tracts with two separate endoscopic carts.

Barcelona

25th Anniversary EAU Congress

16-20 April 2010

Thank you

25th Anniversary EAU Congress

EAU

European
Association
of Urology

©